



PATIENT

Hope Forston

SPECIES

Feline

BREED

DLH

SEX

Female Intact

AGE

4 months

WEIGHT

5.2lbs

INTERPRETED BY

Maggie Machen Lamy,
DVM, DACVIM
(Cardiology)

IMAGING PERFORMED BY

A. Nicastro, DVM

HOSPITAL NAME

Animal Hospital of
South Carolina

REFERRING VET

Dr. Stone

INVOICE

46523

DATE

1/21/26

PRESENTING CLINICAL SIGNS

History: 12/26/2025 presented for acute respiratory distress. Initially had a cough 2 weeks prior; history of URIs. Congested with crackles in lungs. CXR report: mild cardiomegaly. BI patten caudodorsally. Treated with a dose of Lasix in hospital, Rx Lasix
No murmur ausculted. Elevated BNP.

ECHOCARDIOGRAM FINDINGS

2D, m-mode, color flow and doppler imaging is available. The left ventricular wall is normal in dimension. The endocardium appears normal. The papillary muscles are normal in size and architecture. The left atrium is normal in size. The right atrium and ventricle are both mildly enlarged. Linear opacities are seen within the RA, likely tethered to the tricuspid valve. Similar opacities are seen in the distal pulmonary artery as well. The MPA is mildly dilated. The mitral valve is normal in structure and mobility. No MR seen. Normal flow through both the RVOT and LVOT. No obvious TR, AI or PI. No congenital defects are observed. No pleural or pericardial effusion seen. No obvious cardiac tumors.

CARDIAC CHART

FELINE CARDIAC PARAMETERS	BODY WEIGHT (kg)	HR (BPM)	IVSd (cm) (Moise, Pipers)	LVIDd (cm) (Moise, Pipers)	LVWd (cm) (Moise, Pipers)	FS (%)	EF (%)
NORMAL PARAMETER	-----	150-240	0.35-0.55	<2 (mean 1.5)	3.5-0.55	35-67	80-100
PATIENT	2.4	NM	0.35	1.1	0.37	59	92
FELINE CARDIAC PARAMETERS	LA/AO (Boon)	LA/AO HEART BASE (Swe) (Abbott)	LA 2D short axis Base view (cm) (Abbott)		LVOT VEL (m/s)	RVOT VEL (m/s)	E max (m/s)
NORMAL	<1.5	<1.3	<1.2		<1.6	<1.3	<0.9
PATIENT	1.1	1.1	0.9		0.9	1.0	NM

**Note: All measurements based upon multi-modal images and methods. An average value is reported.
Adapted from June Boon, Veterinary Echocardiography, 1998
Abbott J & MacLean H JVIM 2006;20: 111-119, Moise et al. Am J Vet Res 47:1476, 1986. Pipers et al. Am J Vet Res 40:882, 1979.*

INTERPRETATION OF THE FINDINGS & FURTHER RECOMMENDATIONS

Unusual case. The left heart appears normal, ruling out typical HCM. The right heart is enlarged, as is the MPA. What is quite unusual is linear opacities are seen within the right atrium and distal pulmonary artery. In an older animal, these would consistent with a heartworm infestation. That being said, this would be extremely rare in cats, let alone one that is just 4 months old. The relevance of these is likely significant in light of respiratory signs/crackles/CXR changes. Highly recommend a full heartworm panel in this case, with careful consideration of antigen results. Typically adult worms are not able to develop before 6 months; however, this appearance is highly concerning. Consider referral to a local Cardiologist in this unusual case particularly if HW testing is negative, as advanced imaging may shed light on alternative explanations.

For now, no medications are indicated. CHF is unlikely in the absence of effusions in this case, and is likely ruled out. Lasix can be discontinued. Doxycycline would be reasonable if symptoms persist.



PATIENT

Hope Forston

Anesthesia is not advised at this time.

SPECIES

Feline

PLAN: No obvious indication for Lasix therapy. Consider doxycycline if the patient is still tachypneic. Heartworm testing as discussed. Consider referral.

BREED

DLH

Pending results of further work up, recommend recheck echocardiogram in 3-4 months.

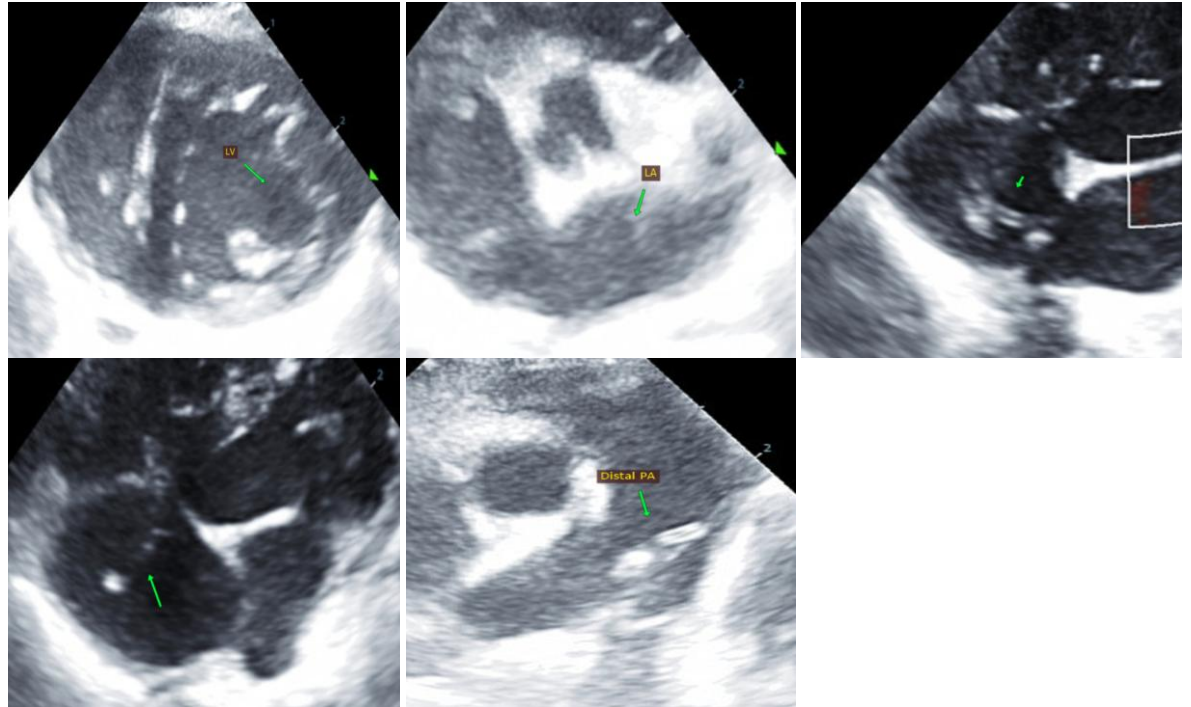
SEX

Female Intact

IMAGES

AGE

4 months



WEIGHT

5.2lbs

INTERPRETED BY

Maggie Machen Lamy,
DVM, DACVIM
(Cardiology)

**IMAGING
PERFORMED BY**

A. Nicastro, DVM

HOSPITAL NAME

Animal Hospital of
South Carolina

REFERRING VET

Dr. Stone

The information and recommendations provided are based on the images presented by the referring veterinarian. No evaluation can be communicated regarding pathology that was not visible in the image/video clips provided.

Thank you for this referral. This report was generated using transcription software, and minor dictation errors may be present. If the clinical or image interpretation does not parallel your findings or if I can be of any further assistance, please contact me.

INVOICE

46523

Maggie Machen Lamy, DVM
Diplomate of the American College of Veterinary Internal Medicine (Cardiology)
info@sonopath.com

DATE

1/21/26



PATIENT

Hope Forston

SPECIES

Feline

BREED

DLH

SEX

Female Intact

AGE

4 months

WEIGHT

5.2lbs

INTERPRETED BY

Maggie Machen Lamy,
DVM, DACVIM
(Cardiology)

**IMAGING
PERFORMED BY**

A. Nicastro, DVM

HOSPITAL NAME

Animal Hospital of
South Carolina

REFERRING VET

Dr. Stone

INVOICE

46523

DATE

1/21/26